

9° Congresso Triennale  
di Anatomia Patologica

SIAPeC-IAP 2022

Centro Congressi Fiera di Padova | 12/15 ottobre 2022

## Cystic neutrophilic granulomatous mastitis (CNGM): an unusual form of granulomatous mastitis

Coppola G.<sup>1</sup>, Pisano A.<sup>1</sup>, Pernazza A.<sup>2</sup>, d'Amati G.<sup>1</sup>, Cerbelli B.<sup>2</sup>.

<sup>1</sup>: Department of Radiological, Oncological and Pathological Sciences, "Sapienza" University of Rome, Rome, Italy.

<sup>2</sup>: Department of Medical-Surgical Sciences and Biotechnologies, "Sapienza" University of Rome, Rome, Italy.

### OBJECTIVES:

Cystic neutrophilic granulomatous mastitis (CNGM) is an extremely rare type of mastitis<sup>1</sup>, often associated with *Corynebacterium species*<sup>2</sup>. Our purpose is to analyze the clinical and pathological features of CNGM.

### MATERIALS AND METHODS:

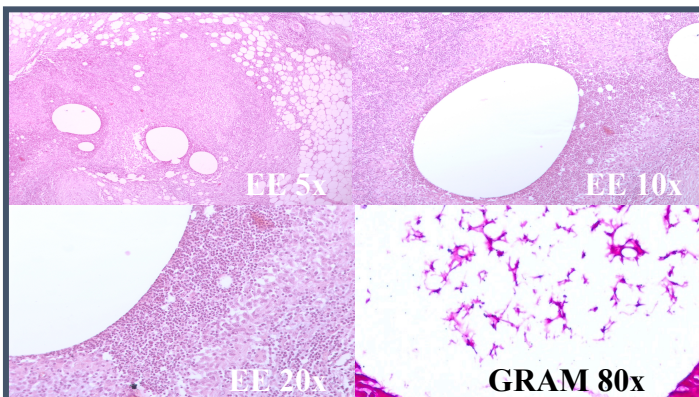
We retrieved all cases of granulomatous mastitis (GM) diagnosed in our Institution from 2018 to 2022. We reviewed all the H&E slides and Gram stains and collected patients' relevant clinical and radiological features.

### RESULTS:

In our series, CNGM accounted for 4 out of 9 cases of GM (44%). Main histological features were the presence of optically empty vacuoles rimmed by neutrophils, with an outer layer of epithelioid histiocytes surrounded by a lymphocytic infiltrate. In 2 of 4 cases some of the vacuoles contained ropey material with rod-shaped, Gram-positive bacilli. Interestingly, the diagnosis was always made on surgical samples from patients with invasive breast cancer; in 3 of 4 cases it was an incidental finding in the breast parenchyma surrounding the neoplasia while in the remaining case it was clinically misinterpreted as an additional focus of cancer<sup>3</sup>.

### CONCLUSION:

CNGM is a specific type of mastitis which, in a subset of cases, can benefit from targeted antibiotic therapy. This recently described entity is probably still under recognized and must be differentiated on histology from other forms of granulomatous mastitis. According to our experience this entity can simulate malignancy on clinical examination and imaging.



### REFERENCES:

- 1) Maung M.H. et al. Cystic neutrophilic granulomatous mastitis - a review of 12 consecutive cases Histopathology 2020 Nov;77(5):781-787. doi:10.1111/his.14187.
- 2) Wang L. et al. Cystic neutrophilic granulomatous mastitis: Corynebacterium species-associated infection with distinct histology. Case Reports Clin Microbiol Infect. 2021 Feb;27(2):236-237. doi: 10.1016/j.cmi.2020.06.037.
- 3) Wang Y. et al. Cystic neutrophilic granulomatous mastitis with corynebacterium and staphylococcus mimicking breast carcinoma. Case Reports. Clin Case Rep. 2018 Oct 10;6(11):2208-2210. doi: 10.1002/ccr3.1801